

# Analysis of Results of Titanium Elastic Nails (TENs) and Ender Nails: A Comparative Study

Prasantakumar Saha<sup>1</sup>, Abirkumar Ghosh<sup>1</sup>, Hibjul Ali Khan<sup>2</sup>, Sagnik Ray<sup>3</sup>, Sudarshan Behera<sup>3</sup>

<sup>1</sup>Assistant Professor, Department of Orthopaedics, Institute of Post Graduation and Medical Research and Seth Sukhlal Karmani Memorial Hospital, Kolkata, West Bengal, India, <sup>2</sup>RMO Cum Clinical Tutor, Department of ???, Institute of Post Graduation and Medical Research and Seth Sukhlal Karmani Memorial Hospital, Kolkata, West Bengal, India, <sup>3</sup>3<sup>rd</sup> Year Post Graduate Trainee, Department of ???, Institute of Post Graduation and Medical Research and Seth Sukhlal Karmani Memorial Hospital, Kolkata, West Bengal, India

## Abstract

**Background:** The management of pediatric femoral fractures has evolved toward a more operative approach in the past decade. It has been noticed that problems such as angulation, malrotation, and limb length discrepancy cannot be effectively controlled by non-operative treatment all the time. Among the various operative treatment such as plating, external fixator, rigid intramedullary nailing, and elastic stable intramedullary nailing has become gold standard now. Titanium elastic nails (TENs) and Ender nails are most commonly used.

**Purpose:** The purpose of this study was to compare the results of TENs and Ender nail in pediatric femoral shaft fracture.

**Materials and Methods:** During the period of February 2010-March 2014, 82 patients with 82 femoral fractures were included in the study. Patients with bilateral femoral fracture, pathological fracture, non-union, were excluded from the study. All the nails were introduced through retrograde approach after close reduction under image intensifier, where close reduction was not possible, the open reduction was done. Among the 82 patients, TENs were done in 40 patients, and Ender nails were done in 42 patients. Patients were followed up for a period of 2-4 years.

**Results:** There was no difference between the two groups with regard to demographic profile. No statically difference was found in regard to fracture union, hospital stay, and weight bearing. No difference in result was found according to the Flynn criteria.

**Conclusion:** As there is no difference between the two groups, Ender nail is a good alternative compared to TENs as it is lower cost.

**Key words:** Femoral fracture, Nail, Titanium

## INTRODUCTION

Throughout the centuries, the goal of orthopedics and traumatology has been to return the patient to his pre-trauma state as quickly as possible. Femoral shaft fracture comprises 2% of all fractures in children and adolescents. For many years conservative treatment with traction and hip spica has been the gold standard for all femoral fractures in children and adolescents with relatively good results. In many occasion, unacceptable alignment and

squeal of prolonged immobilization are the end result. At present surgical methods are preferred since they are associated with early mobilization and fast return to function. Although external fixator has the advantages of easier application, early mobilization, and avoid casting; but the most important disadvantages are pin site infection, scarring refracture, and malunion. Open reduction and internal fixation with plate and screws have the advantages of rigid fixation, but the disadvantages are a large scar, possible refracture after plate removal. About rigid nail, the most important thing concern about is osteonecrosis of the femoral head, if piriformis fossa is used as entry portal.

The flexible intramedullary nails (Ender and Titanium elastic nails [TENs]) are ideal for pediatric femoral fracture due to ease of use, prevention of any traction, and cast complications. The treatment outcomes reported by flexible nails are very successful for this age group.<sup>1-3</sup> Technically

### Access this article online



www.ijss-sn.com

Month of Submission : 00-0000  
 Month of Peer Review : 00-0000  
 Month of Acceptance : 00-0000  
 Month of Publishing : 00-0000

**Corresponding Author:** Prasantakumar Saha, 6A/1B Raja Bagan Lane, Dum Dum, Kolkata - 700 030, West Bengal, India.  
 Phone: 9903151908. E-mail: prasantakumarsahaortho@gmail.com

lesser traumatization, use of mostly the retrograde surgical technique, and the lack of harm to the growth cartilage, use of nails with smaller diameter and absence of drilling procedure are among the advantages of flexible nail.<sup>4</sup> Furthermore, the fixation fulfills the three point fixation principle, since the nails are medially and laterally placed. The elasticity and stress distribution of the flexible nails facilitate the callus formation.

The aim of our study was to compare the results of TENs and Ender nails.

## MATERIALS AND METHODS

This is an institutional based observational prospective study carried out from February 2011 to March 2015, in our institution (IPGMER and SSKM Hospital), after getting permission from the Ethical Committee. All the patients have been counseled about the pros and cons of the study, and the written consent has been taken. The main catchment area of our institution is Kolkata and its suburban area. Among this period, the study was conducted among 82 patients. The patients were randomly selected for TENs and Ender nails. Patients with an open fracture, non-union, fracture more than 3 weeks old and bilateral fracture shaft femur, pathological fracture were excluded from this study. All the patients are within 5-16 years age group. Position of the patient is supine in a free position or on a fracture table with a traction boot. If a fracture reduction can be accomplished by manual traction, a standard table may be used. The fracture is reduced under image intensifier. If the close reduction is not possible, then the open reduction is done. The entry point of the nail is 2.5 cm-3.0 cm proximal to the physis. We generally use an awl to penetrate the near cortex. The nail is introduced with the help of inserter under image intensifier. The fracture is reduced, and the nails are introduced. Advancement of the nails is continued until it is just proximal to the physis. In case of Ender nail, it is just impact over the distal femur (Figures 1 and 2). In case of TENs, nails are cut 1 cm-2 cm away from bone and bent 10-15° and impact over the distal femur (Figures 3 and 4). Patients were followed for a period of at least 2 years.

## RESULTS

From February 2010 to March 2015, 82 patients with 82 fracture shaft femur admitted in our institution were included in our study. According to the orthopedic and trauma association (OTA) criteria type 32A: 30 patients in TENs and 32 in Ender group, respectively, type 32B: 8 patients in each group, type 32C: 2 patients in each group (Figure 5).

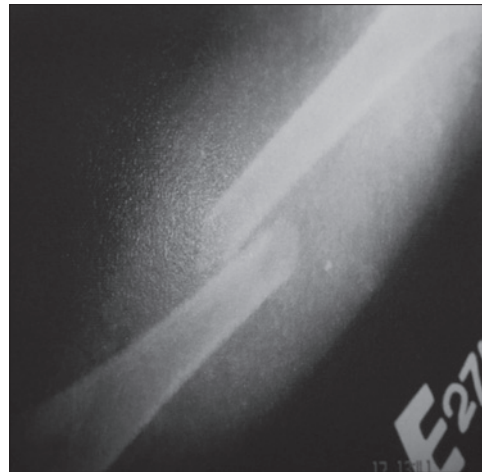


Figure 1: Fracture shaft femur

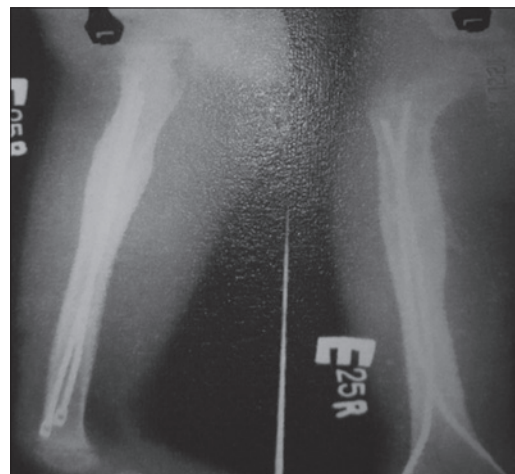


Figure 2: Fracture united after Ender nailing

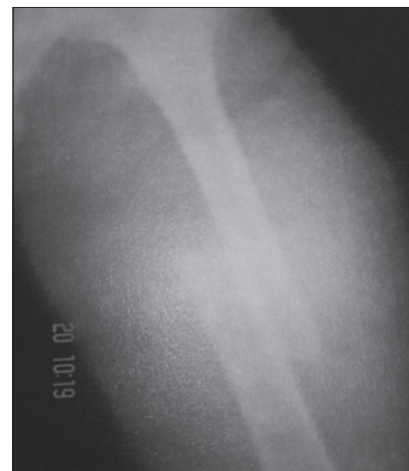

Figure 3: Fracture shaft femur

There was no significant difference between the groups with regard to demographic profile (Table 1). There was no difference between the groups as measured by linear relationship in respect to mechanism injury fall (15 patients

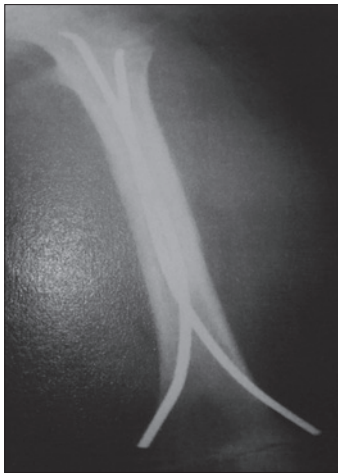

Figure 4: Fracture united after Titanium elastic nailing

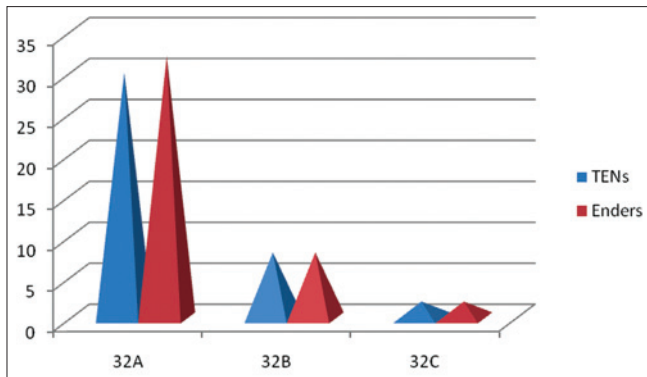


Figure 5: Distribution of fracture

Table 1: Distribution of demographic data

Parameters	TENS (40)	Enders (42)	P value
Male gender	23	29	0.278
Mean age	10.5 years	9.9 years	0.250
Associated systematic injury	9	12	0.529
Injury severity score	9.9	6.6	0.087

TENs: Titanium elastic nails

in TENS and 8 patients in Ender), motor vehicle accident (11 and 17, respectively), motor vehicle – pedestrian (6 in each group), sports related injury (2 and 5, respectively), bicycle accident (3 and 1, respectively) and other mechanism (4 and 2, respectively) (Figure 6).

Among the TENS group 15 patients need open reduction (average operative time – 45 min) 25 patients, close reduction done (average operative time – 35 min). Among the Ender nail group, 13 patients need open reduction (average operative time – 40 min), and 29 patients need close reduction (average operative time 25 min). In case of close reduction, blood loss is minimal and in open reduction average blood loss in both cases 80 ml and 70 ml, respectively (Figure 7).

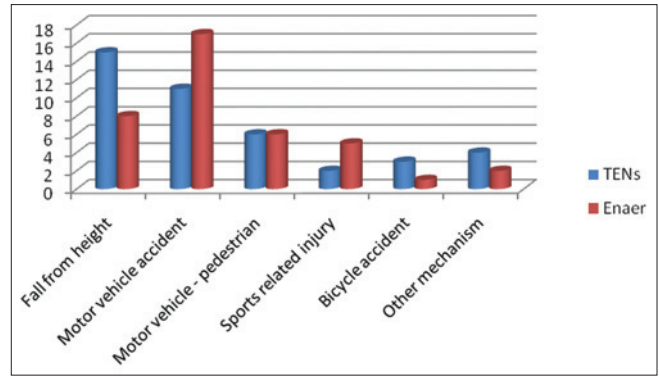


Figure 6: Distribution of mode of injury

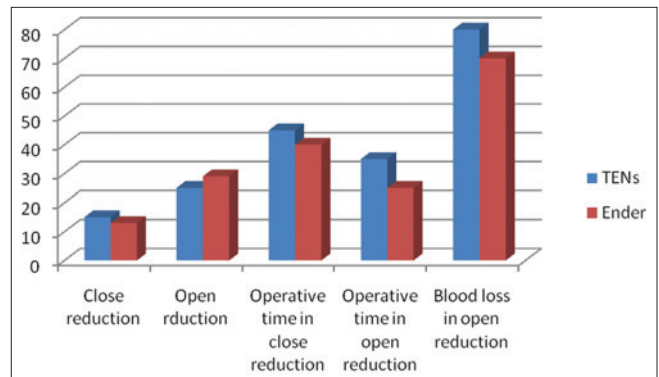


Figure 7: Operative details

Post-operatively there was no difference between the groups in respect of quality of reduction ( $P = 0.122$ ). The average hospital stay was  $7.5 \pm 4.4$  days in TENs group and  $6.9 \pm 3.5$  days in Ender group. The average union time 7.2 weeks was in TENs group and 6.9 weeks in Ender group, respectively. All the patients have a full range of hip and knee motion.

The total number of complication was in TENs group 11 and in Ender group 12. About 8 patients in TENS group have pointed nail, among them 3 patients require surgery. Totally 5 patients, symptoms are gone after removal of nail. 6 patients in Ender group have pointed nail but no patients require surgery. Nearly, 5 patients and 4 patients in TENS and Ender group have a superficial infection, which was treated with antibiotics. Limb length discrepancy was found in 9 patients in TENs group. The average limb length discrepancy is 1.7 cm (1-2.4 cm). Only 2 patients have more than 2 cm limb length discrepancy. In Ender group, 7 patients have limb length discrepancy (average-1.5 cm). No patients have more than 2 cm discrepancy. Malunion (angulations more than  $10^\circ$  in both sagittal and coronal plane) was found 6 patients in TENS group and 2 patients in Ender group. Malunion was particularly seen in long oblique and spiral fracture (Figure 8).

According to the Flynn criteria, among TENs group excellent result seen in 26 patients, good 12 patients and

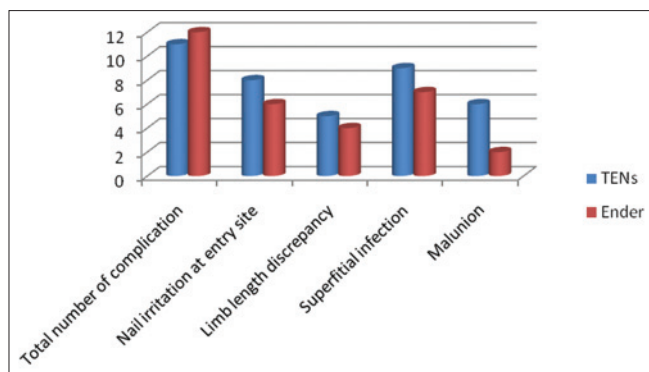


Figure 8: Total number and distribution of complication

poor in 2 patients. In Ender group 28 patients have an excellent result, 13 patients have good, and 1 patient has the poor result (Figure 9). There was no statically difference between the groups ( $P < 0.001$ ). Femoral anteversion angle was found equal or close to the opposite side, which had no statically significance.

## DISCUSSION

It has been commonly accepted that surgical intervention is indicated for pediatric femoral shaft fracture in case of an open fracture, multiple trauma, concomitant head injuries, burns, and neuromuscular wounding. However, the number of publications suggesting that surgery can also be considered for isolated femoral fractures is gradually increasing. Due to achievements such as earlier return to function, no or less joint flexibility, lesser wound tumor compare to other surgical methods, lesser complications of infection, refracture, and malunion, earlier mobilization in patients with multiple trauma, reduction in the duration and cost of hospitalization, intramedullary nailing has become one of the methods of choice in children too.<sup>1,5-8</sup>

In children, the interventions using flexible intramedullary nails are technically easier than the use of rigid nails.<sup>1,4,9</sup> It allows movement at the fracture site, which helps in callus formation, avoid physis, and blood supply to the femoral head. The use of intramedullary nailing in children can be antegrade or retrograde approach. We were using retrograde approach.

The most common complication of femoral shaft fracture is the discrepancy between lower extremity length, and is frequent between 2 and 10 years of age.<sup>1,7,8</sup> No significant discrepancy was found between the limb length in the intramedullary nailing carried out in older children and adolescents.<sup>4,6</sup> Heinrich<sup>7</sup> reported that 22% of their patients had lengthening over 5 mm, and 11% had shortening under 5 mm. In our study, we found only 2 patients have more than 2 cm limb length discrepancy in TENs group.

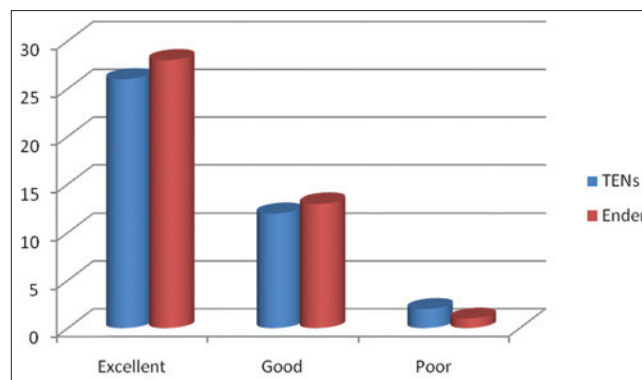


Figure 9: Distribution of result according to Flynn criteria

Another common complication of pediatric femoral fractures is the malunion. Herdon *et al.* reported that clinically significant malunion developed in 7 of 24 patients who were treated with traction while in 21 patients who were treated with an elastic nail, no significant malunion was seen. In the antegrade elastic nailing series of Carey and Galpin,<sup>1</sup> no significant rotational and angular deformity were found.

Other recognized complication after fixation with TENs is the pain at the entry point of the nail caused by irritation of soft tissue. In order to prevent soft tissue irritation, only a small part of the nail should be left outside the distal metaphyseal cortex and nails must never bent in the soft tissue.<sup>10,11</sup> Luhmann *et al.*<sup>11</sup> indicated that the technical problem can be minimized if the part or the nail, which is left outside the femur is smaller than 2.5 cm, and the biggest diameter nail is used. The soft tissue irritation by the Ender nail is less because the end of the nail is smooth, and it is flushed with the bone.

Flexible intramedullary nailing produces excellent result in children and adolescents with fewer nail complication rates. There was no significant statically differences in result between TEN and Ender nail group.

## CONCLUSION

The cost of Ender nail is much lesser than the TEN. Our study states that there is no significant statically difference between costly TENs and less expensive Ender nail. In our country, less expensive Ender nail is a good alternative to TENs.

## REFERENCES

- Carey TP, Galpin RD. Flexible intramedullary nail fixation of pediatric femoral fractures. *Clin Orthop Relat Res* 1996;110-8.
- Flynn JM, Hresko T, Reynolds RA, Blasier RD, Davidson R, Kasser J. Titanium elastic nails for pediatric femur fractures: A multicenter study of early results with analysis of complications. *J Pediatr Orthop* 2001;21:4-8.

3. Mazda K, Khairouni A, Penneçot GF, Bensahel H. Closed flexible intramedullary nailing of the femoral shaft fractures in children. *J Pediatr Orthop B* 1997;6:198-202.
4. Ligier JN, Metaizeau JP, Prévot J, Lascombes P. Elastic stable intramedullary nailing of femoral shaft fractures in children. *J Bone Joint Surg Br* 1988;70:74-7.
5. Galpin RD, Willis RB, Sabano N. Intramedullary nailing of pediatric femoral fractures. *J Pediatr Orthop* 1994;14:184-9.
6. Winkquist RA, Hansen ST Jr, Clawson DK. Closed intramedullary nailing of femoral fractures. A report of five hundred and twenty cases. *J Bone Joint Surg Am* 1984;66:529-39.
7. Heinrich SD, Drvaric DM, Darr K, MacEwen GD. The operative stabilization of pediatric diaphyseal femur fractures with flexible intramedullary nails: A prospective analysis. *J Pediatr Orthop* 1994;14:501-7.
8. Öztürkmen Y, Doğrul C, Balioglu MB, Karli M. Intramedullary stabilization of pediatric diaphyseal femur fractures with elastic Ender nails. *Acta Orthop Traumatol Turc* 2002;36:220-7.
9. Huber RI, Keller HW, Huber PM, Rehm KE. Flexible intramedullary nailing as fracture treatment in children. *J Pediatr Orthop* 1996;16:602-5.
10. Aktas S, Sarislik H. Çocuk femur cisim kırıklarında. *Acta Orthop Traumatol Turc* 1997;31:198-202.
11. Linhart WE, Roposch A. Elastic stable intramedullary nailing for unstable femoral fractures in children: Preliminary results of a new method. *J Trauma* 1999;47:372-8.

**How to cite this article:** Saha P, Ghosh A, Khan HA, Ray S, Behera S. Analysis of Results of Titanium Elastic Nails (TENs) and Ender Nails: A Comparative Study. *Int J Sci Stud* 2015;3(4):1-5.

**Source of Support:** Nil, **Conflict of Interest:** None declared.

**Author Queries???**

AQ1: Kindly provide history details

AQ2: Kindly provide department.

AQ3: Kindly mention Dr or Prof??

AQ4: Kindly check the author name does not match with reference list.